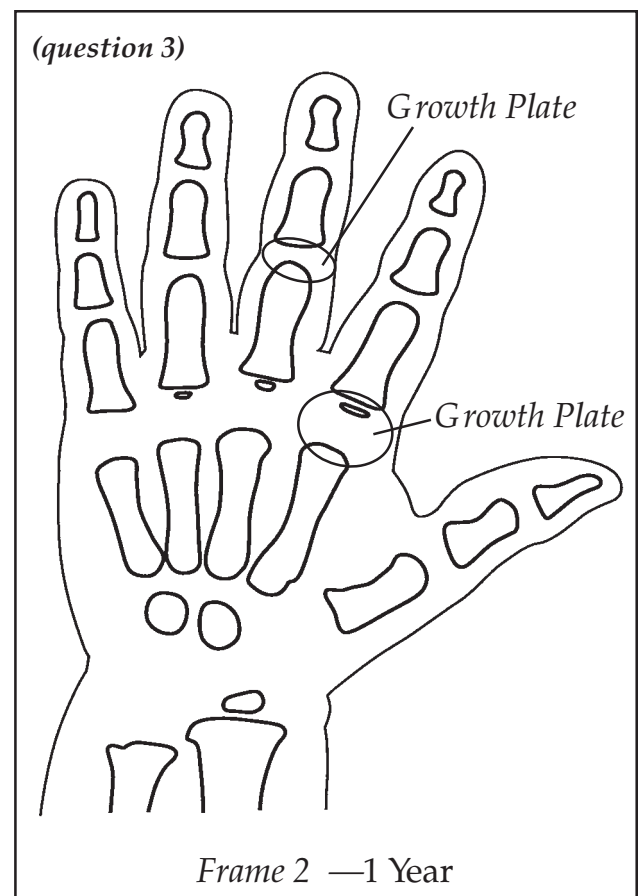
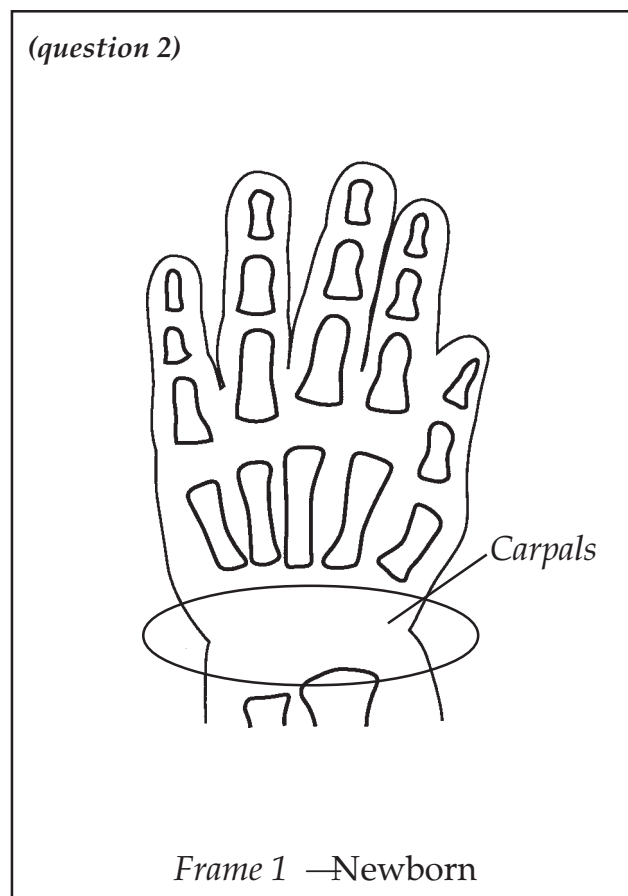


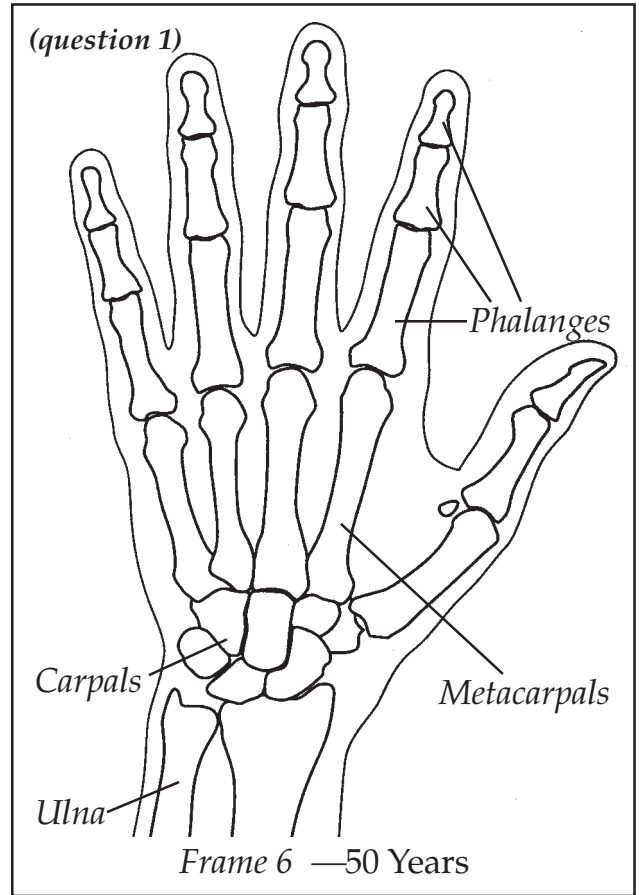
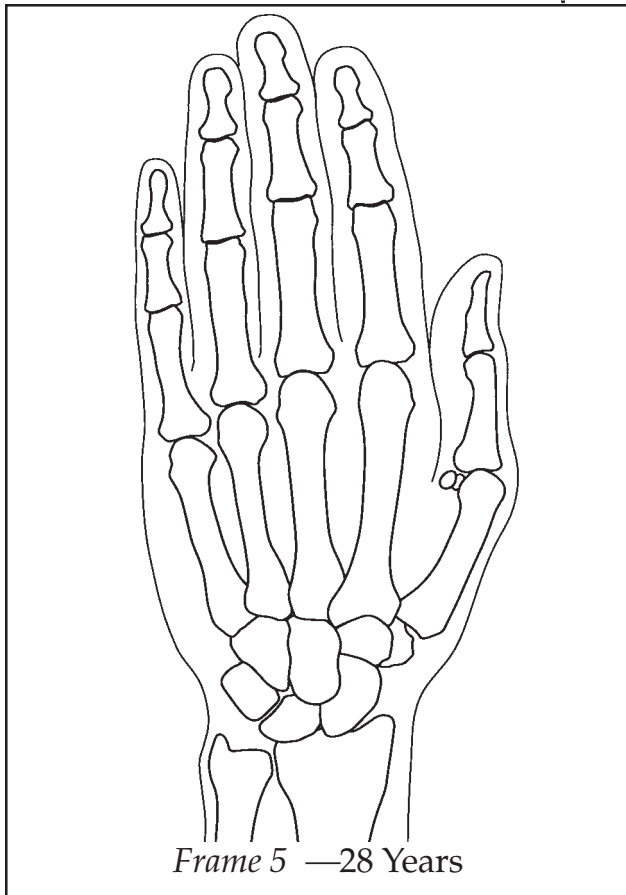
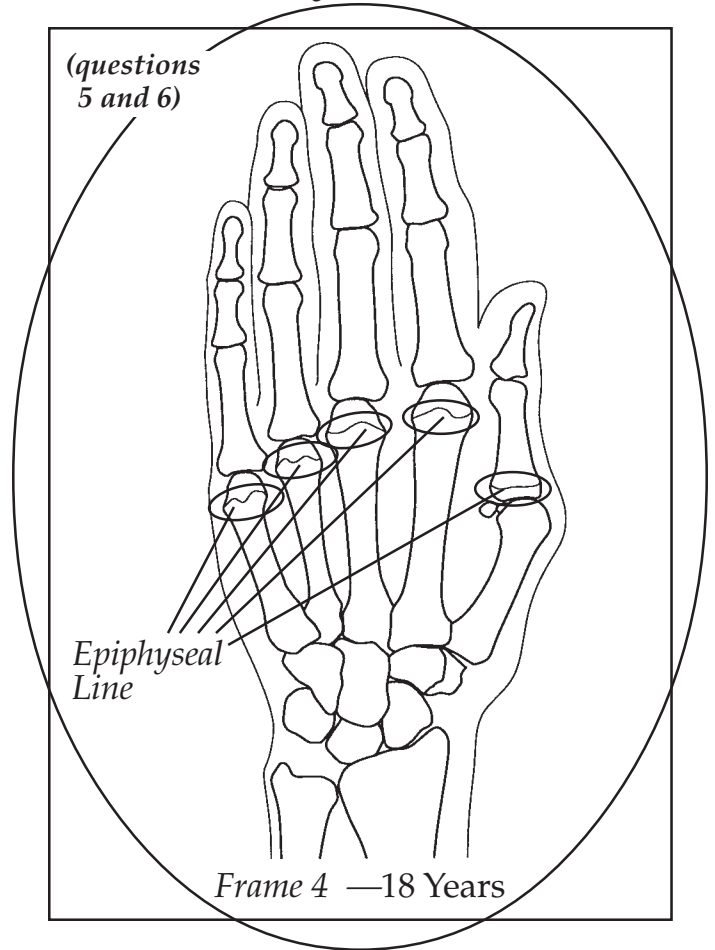
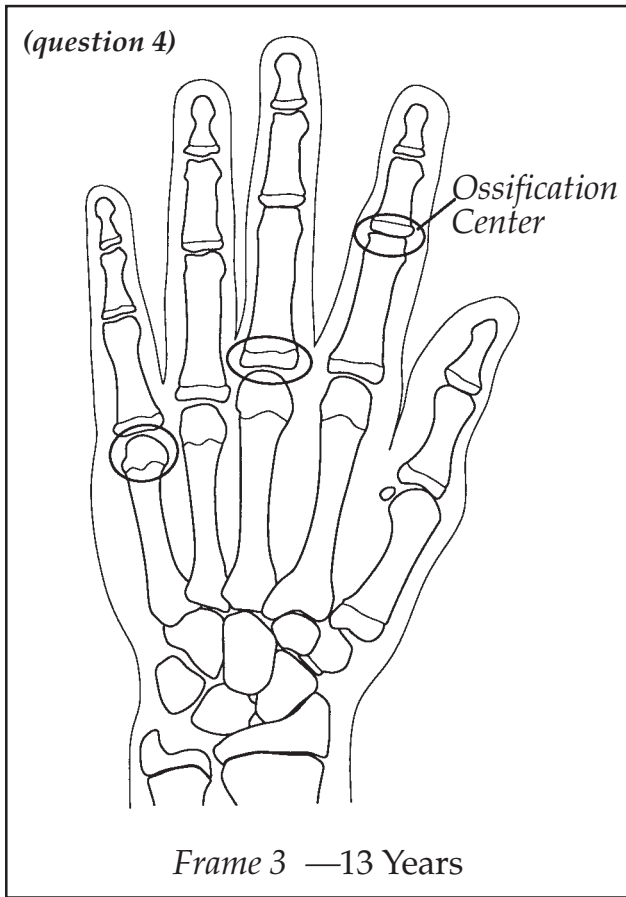
## ACTIVITY 2I - THE AGING HAND

### Answer Key

1. Look at frame 6. Carpals, metacarpals, phalanges, radius, and ulna are circled and labeled.
2. Look at frame 1. The carpal area is circled and labeled.
3. Look at frame 2. Growth plates are circled and labeled where a space (cartilage) occurs between the individual phalange bones or between the phalanges and metacarpals.
4. Look at frame 3. An ossification (bone) center should be circled and labeled. This should be an area where a space occurred in an earlier frame.
5. Look at frame 4. An epiphyseal line should be circled and labeled on a metacarpal. Show and circle frame 4 completely.
6. Frame 4 should be circled; no further major changes occur after this frame.
7. The X-ray drawing is from a six-year and ten-month-old female. Students should state that they would place this photo between frame 2 and frame 3. Some of the carpal bones are present. Also, ossification (bone) centers are present at the ends of some of the bones.



# ACTIVITY 2I - THE AGING HAND - Answer Key



UNIT 12